

# Full-arch rehabilitation with tissue level implants in a severely resorbed mandible: 4-year follow-up

Louwrens Swart<sup>1</sup> and Paul van Zyl<sup>2</sup>

## Introduction

The evolution of dental implantology has changed the management of edentulous patients, providing a predictable solution for the restoration of oral function and esthetics. With advancements in implant design and surgical techniques, immediate loading protocols have gained considerable attention, offering patients the benefits of accelerated treatment and improved satisfaction.

Straumann® TLX SLActive® implants represent a cutting-edge advancement in implant dentistry, characterized by their tapered, tissue-level design and innovative surface characteristics aimed at optimizing osseointegration and long-term stability.

A growing amount of scientific literature supports immediate loading protocols, demonstrating favorable clinical outcomes and high implant survival rates. Recent studies have underscored the feasibility and efficacy of immediate loading in full-arch rehabilitations, highlighting its potential to shorten treatment times and enhance patient satisfaction without compromising long-term success.<sup>1,2</sup>

However, despite the promising evidence, the literature remains relatively underexplored regarding the application of immediate loading protocols in conjunction with TLX implants for full-arch rehabilitations in the mandible. Therefore, this case report aims to contribute to the existing evidence by documenting the clinical outcomes of immediate loading with four Straumann® TLX implants in the lower jaw with a 4-year follow-up.

## Initial situation

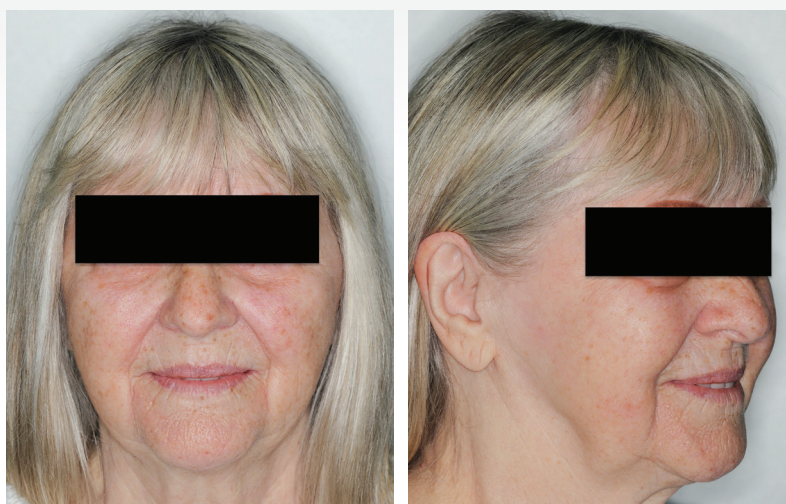We present the case of a 74-year-old female patient classified as healthy (ASA I), a non-smoker, with no medications or allergies. She sought evaluation at our clinic due to dissatisfaction with her current prostheses. The patient has been wearing full prostheses for an extended period, experiencing significant challenges in eating and speaking as the lower prosthesis constantly moves, resulting in painful sores and discomfort. This condition has adversely affected her health and overall quality of life. Consequently, she expressed a desire for a stable, fixed, full-arch rehabilitation.

The extraoral examination showed the lower third slightly diminished and slight retrusion of the teeth. (Figs. 1,2)

After the removal of the full prostheses, an intraoral examination was conducted. The examination revealed a view of the edentulous mandible with an uneven vertical ridge, accompanied by muscle and fibrous bands. Sore spots and ulcerations were observed (Fig. 3). The panoramic view showed severely resorbed ridges in the mandible (Fig. 4).

<sup>1</sup> Dr Louwrens Swart  
BChD, MChD (MFOS),  
Private Practice,  
Cape Town, South Africa  
lcswart@mweb.co.za

<sup>2</sup> Dr Paul van Zyl  
BChD, MChD (Prost),  
Private Practice,  
Cape Town, South Africa



In terms of surgical classification the patient was classified as complex and, in terms of prosthodontics, between complex and advanced according to the SAC system (Fig. 5).

### Treatment planning

After discussing various treatment options extensively with the patient, it was decided to proceed with a full-arch rehabilitation using four Straumann® TLX implants. This decision was based on the severely resorbed mandible and the patient's desire for a stable prosthesis.

The treatment workflow included:

1. Prosthetic and esthetic analysis.
2. Digital planification and lower denture converted to a surgical guide.
3. Four Straumann® TLX implants placed between the anterior loops of the mental nerves.
4. Delivery of the temporary prosthesis.
5. The definitive prosthesis includes a Straumann® Cares milled titanium bar attached to the Tissue Level portion of TLX implants. No intermediary abutments were required. The titanium at the bottom of the prosthesis and the implant connection facilitates the maintenance and resistance in the cantilever.

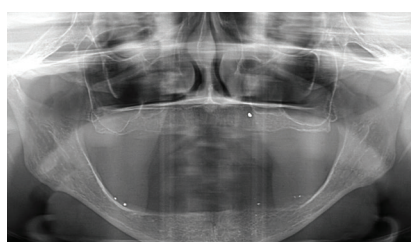
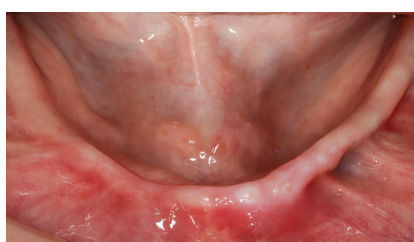### Surgical procedure

Prior to the surgery, local anesthesia with lidocaine 2% with epinephrine 1:100k was administered. A mucoperiosteal flap was then carefully created, with a crestal incision and a distal relieving incision placed approximately 10 mm behind the mental foramina, while ensuring preservation of the mandibular nerve (Fig. 6).

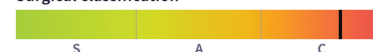Vertical ridge reduction was performed to level the alveolar crest, facilitating the creation of the desired bone architecture. This procedure was essential to ensure adequate bone width for successful implant placement and to provide sufficient space for the prosthetic hardware (Fig. 7). The surgical procedure included both bone reduction and implant placement, effectively minimizing trauma and the necessity for separate interventions.

The implant placement planning was conducted using coDiagnostiX® software, an AI-powered dental treatment planning tool. The software for 3D diagnostics and implant planning is designed for precise surgical planning of dental implants, including TLX Implants available within its digital library. This procedure took into account the distribution between the anterior loops of the mental nerves for optimal implant positioning (Fig. 8).

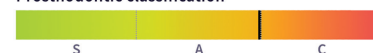The positions for implant placement were determined and



#### Surgical classification



#### Prosthodontic classification



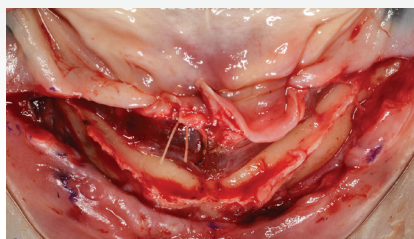


Fig. 6

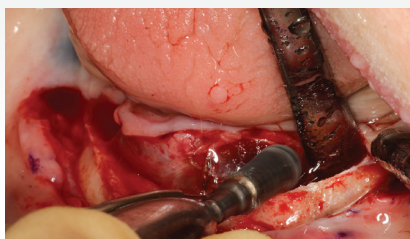


Fig. 7

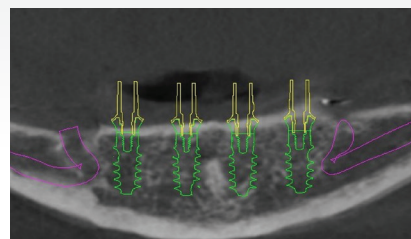


Fig. 8

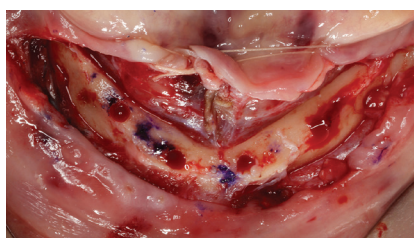


Fig. 9.

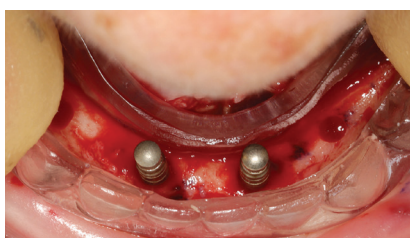


Fig. 10

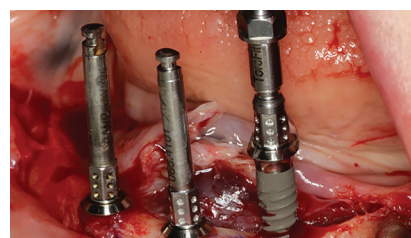


Fig. 11

marked, with clear identification of the mental nerves (Fig. 9).

The drill templates were utilized to guide pilot-hole drilling, and CT was conducted to evaluate the accuracy of the pilot holes. For preparing the implant bed, the Straumann® Modular Cassette was used, following the pilot drilling protocol depending on the bone density. This provides the adaptability to customize the preparation of the implant bed according to the specific bone quality and anatomical circumstances of each patient. Pilot holes were drilled with the pilot drill (ø2.2 mm) to full implant length. The subsequent drills were used following the drilling protocol, taking into consideration the fact that the drill tip, designed to accommodate the function of the drills, is up to 0.5 mm longer than the insertion depth of the implant. The correct positions were verified using the diagnostic template (Fig. 10).

The Straumann® TLX Implants were placed using the handpiece, without exceeding the recommended maximum speed of 15 rpm. The parallelism of the Straumann® TLX implants was evaluated, a final torque of at least 35 Ncm was achieved, and radiographic control was conducted

with healing caps in place (Fig. 11).

### Prosthetic procedure

An immediate-load prosthesis, designed with a shortened dental arch, was placed within 24 hours of the surgery (Fig. 12). Occlusion was checked, and oral hygiene instructions were given.

At the suture removal appointment, healing was noticed to be uneventful.

After a healing period of 3 months, a new impression was taken to define the shape of the Straumann® Cares® milled titanium bar (Figs. 13,14).

The definitive prosthesis was evaluated intraorally, and oral hygiene instructions were provided, along with a check of the occlusion. Radiographic control was conducted during the delivery of the prosthesis. The final outcome revealed excellent health of both hard and soft tissues (Fig. 15).

### Treatment outcomes

After a 2-year follow-up, an intraoral examination was conducted to assess the condition of the definitive prosthesis

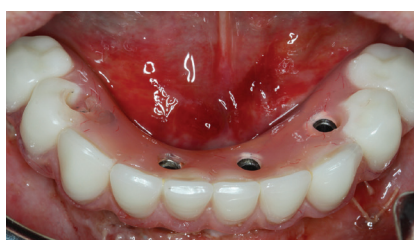

Fig. 12

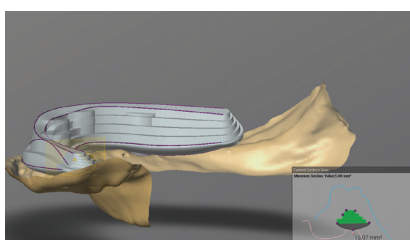


Fig. 13

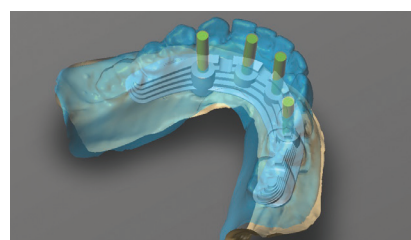


Fig. 14

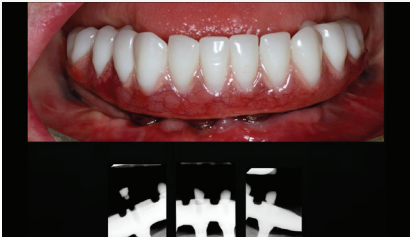

Fig. 15

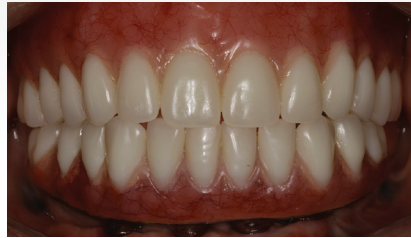

Fig 16




Fig. 17

and its relationship with the upper antagonist. The examination revealed good stability, and occlusal adjustments were not necessary (Fig. 16). Additionally, radiographic control after 2 years confirmed satisfactory outcomes (Fig. 17). The extraoral photos demonstrated a nice smile with good lip support and an esthetically pleasing profile (Figs. 18,19).

After a 4-year follow-up, an examination was conducted to assess the condition of the prosthesis. The prosthesis was in optimal condition, and the patient was delighted as her treatment outcomes were preserved over time. The extraoral results showcased a stable outcome, with the patient expressing satisfaction with the results (Fig. 20). The quality of the extraoral and panoramic images is less than optimal since they were provided by the patient after relocating from the country. A panoramic radiograph was taken as a control

measure, revealing no abnormalities or concerns (Fig. 21).

Following the latest follow-up appointment the patient stated: "I could never believe that these implants could be so natural and comfortable in my mouth with absolutely no discomfort whatsoever. The actual operation and dental work performed in 2020 by Dr. Swart was amazing, just brilliant. My teeth do not move around or need repositioning. They are well and truly fixed in place. I am exceedingly happy with the results that I have attained. I would, without any reservations, highly recommend this trailblazing procedure for a better quality of dental life."

#### Author's testimonial

An immediately loaded hybrid prosthesis is a highly predictable and stable solution for an edentulous mandible

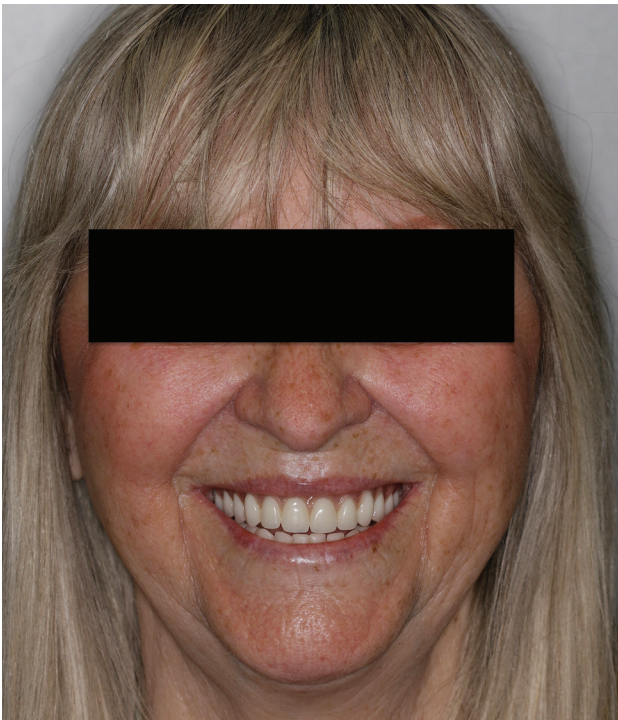

Fig. 18

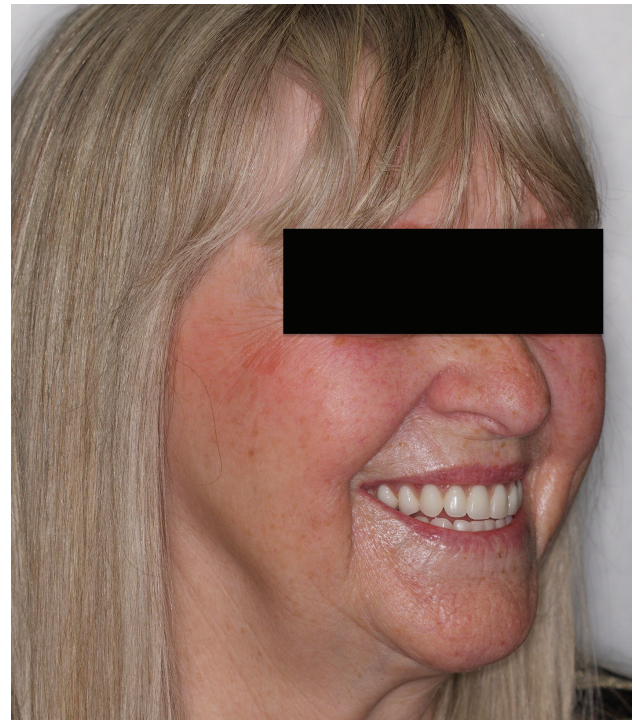

Fig. 19

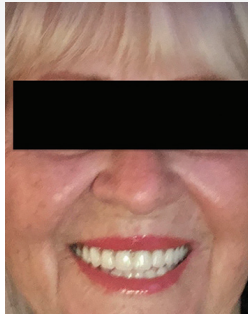

Fig. 20

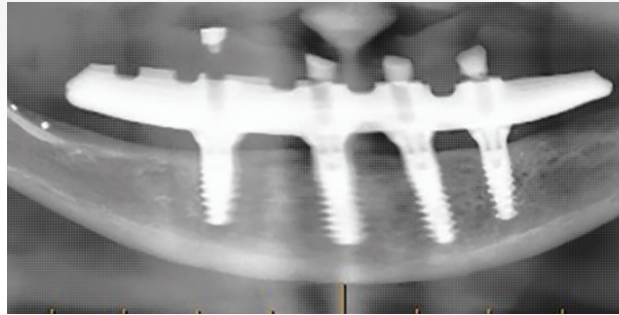


Fig. 21

if no vertical bone is available behind the mental foramina for implants. During this surgery, the innominate blood vessel was identified to prevent intra-operative bleeding, which can lead to potentially life-threatening swelling and airway compromise; also, the anterior loop of the mental nerve was not easily identifiable on 3D X-ray analysis; after positive clinical identification, the alveolar ridge can be reduced to accommodate the width of the implants as well as the height of prosthetic hardware as needed. A stent is always used to ensure that the implants are correctly positioned to support the hybrid prosthesis.

### References

- Peñarrocha-Oltra D, Covani U, Peñarrocha-Diago M, Peñarrocha-Diago M. Immediate loading with fixed full-arch prostheses in the maxilla: review of the literature. *Med Oral Patol Oral Cir Bucal*. 2014 Sep 1;19(5):e512-7.
- Gallardo YNR, da Silva-Olivio IR, Gonzaga L, Sesma N, Martin W. A Systematic Review of Clinical Outcomes on Patients Rehabilitated with Complete-Arch Fixed Implant-Supported Prostheses According to the Time of Loading. *J Prosthodont*. 2019 Dec;28(9):958-968.

*Reprinted with permission from youTooth, 31.May 2024*